



Cranio-maxillofacial

# Implant Directions®

Vol. 10 N° 3      September 2015      English Edition



**CASE REPORT:**  
IMMEDIATE STRATEGIC IMPLANT® RESTORATION OF THE MAXILLA AFTER REMOVAL OF A  
FULLY IMPACTED, HORIZONTALLY RETENTIVED CANINE

IHDE S., IHDE A., LYSENKO V.

ISSN 1864-1199 / e-ISSN 1864-1237

# OFFPRINT



The Foundation of Knowledge

## Editorial board

### Managing editor

Dr. Mayur Khairnar  
drmayurkhairnar@gmail.com

Dr. Vivek Gaur  
drvivekgaur@yahoo.co.in

### Coordinating editor

N. N.

### Editorial board (in alphabetic order)

Dr. Yassen Dimitrov, Bulgaria  
Za. Stephan Haas, Germany  
Prof. Dr. Vitomir S. Konstantinovic, Serbia  
Dr. Valeri Lysenko, Ukraine  
Katarina Markova, Prague  
Jura Mitruschenkow, Moskow  
Dr. Gerald Schillig, Germany  
Dr. Narender Singh, India  
Dr. Katrin Tost, Greece

### Evidence reports and Critical Appraisals

IF Research & Evidence Dept.

### Single Issue Price

Euro 30

### Annual Subscription

Euro 120

### Copyright

Copyright ©2006 - 2015 by  
International Implant Foundation  
DE- 80802 Munich / Germany  
www.implantfoundation.org

### Contact

publishing@implantfoundation.org

### CMF.Impl.dir.

ISSN 1864-1199  
e-ISSN 1864-1237

### Disclaimer

#### Hazards

Great care has been taken to maintain the accuracy of the information contained in this publication. However, the publisher and/or the distributor and/or the editors and/or the authors cannot be held responsible for errors or any consequences arising from the use of the information contained in this publication. The statements or opinions contained in editorials and articles in this publication are solely those of the authors thereof and not of the publisher, and/or the distributor, and/or the IIF.

The products, procedures and therapies described in this work are hazardous and are therefore only to be applied by certified and trained medical professionals in environment specially designed for such procedures. No suggested test or procedure should be carried out unless, in the user's professional judgment, its risk is justified. Whoever applies products, procedures and therapies shown or described in this publication will do this at their own risk. Because of rapid advances in the medical science, IF recommends that independent verification of diagnosis, therapies, drugs, dosages and operation methods should be made before any action is taken.

Although all advertising material which may be inserted into the work is expected to conform to ethical (medical) standards, inclusion in this publication does not constitute a guarantee or endorsement by the publisher regarding quality or value of such product or of the claims made of it by its manufacturer.

#### Legal restrictions

This work was produced by IF Publishing, Munich, Germany. All rights reserved by IF Publishing. This publication including all parts thereof, is legally protected by copyright. Any use, exploitation or commercialization outside the narrow limits set forth by copyright legislation and the restrictions on use laid out below, without the publisher's consent, is illegal and liable to prosecution. This applies in particular to photostat reproduction, copying, scanning or duplication of any kind, translation, preparation of microfilms, electronic data processing, and storage such as making this publication available on Intranet or Internet.

Some of the products, names, instruments, treatments, logos, designs, etc. referred to in this publication are also protected by patents and trademarks or by other intellectual property protection laws« (eg. «IF», «IIF» and the IF-Logo) are registered trademarks even though specific reference to this fact is not always made in the text.

Therefore, the appearance of a name, instrument, etc. without designation as proprietary is not to be construed as a representation by publisher that it is in the public domain.

Institutions' subscriptions allow to reproduce tables of content or prepare lists of Articles including abstracts for internal circulation within the institutions concerned. Permission of the publisher is required for all other derivative works, including compilations and translations. Permission of the publisher is required to store or use electronically any material contained in this journal, including any article or part of an article. For inquiries contact the publisher at the adress indicated.

## Case Report

### Immediate Strategic Implant® restoration of the maxilla after removal of a fully impacted, horizontally retentive canine

#### Authors:

Dr. Stefan Ihde  
Dr. Antonina Ihde  
S. Resort 1  
MNE-85315 Vrba/Tudorovici  
Montenegro

Dr. Valeriy Lysenko  
St. Druzhby Narodiv, 269, a.38  
UA-61183 Kharkiv  
Ukraine

#### Abstract

Especially when retentive and impacted teeth have to be removed before providing dental implant therapy, long healing times have to be taken into account if conventional 2-stage implants are used. A fast and effective treatment is possible however with the Strategic Implant®. These implants require only cortical anchorage in the 2nd cortical and they require immediate splinting (with each other or in rare cases to teeth). The initial bone height (i.e. the distance between the 1st and 2nd corticals) is of no importance for the success of the Strategic Implant®, as long as a resorption stable 2nd or 3rd cortical can be reached and engaged. This case report shows how this principle is applied in a case with a horizontally impacted canine in the upper jaw.

**Keywords:** Impacted and retentive canine, upper jaw, Strategic Implant®, immediate loading, cortical engagement.

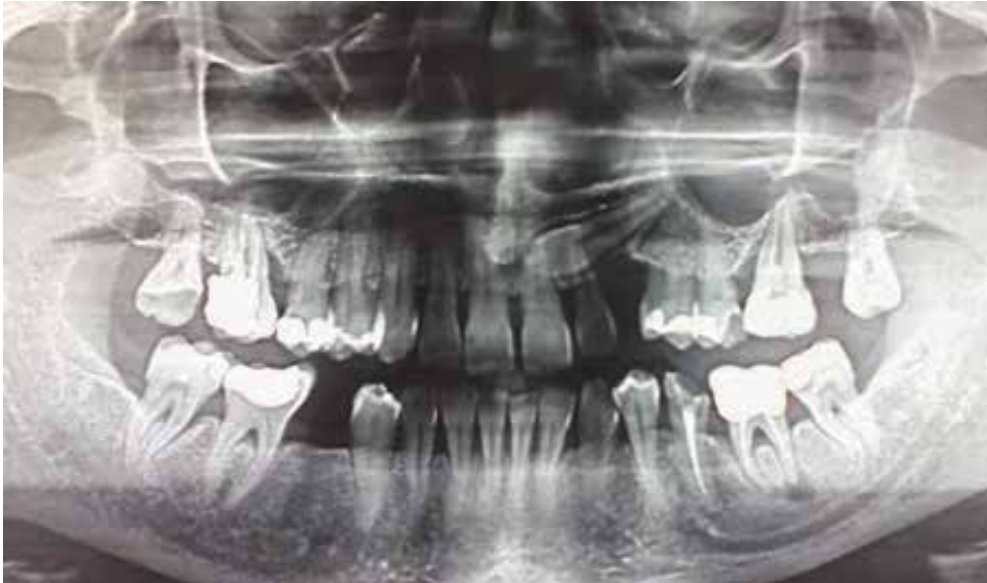#### 1. Introduction

In (conventional) crestal implantology the amount of vertical (mainly spongy) bone is important when it comes to estimating the possibility and the chances of and restoration using such implants. Hence in most cases even up to today immediate implant placement and immediate restorations are rarely done with such implants. One of the reasons for the conservative approach, which includes first extractions, then a waiting time for the bone's healing and finally a 2-stage approach with healing time is, that such implants are equipped with rough surfaces which require being fully submerged into bone to avoid bacterial colonisation.

The Strategic Implant® however is equipped with the highly polished «Noitis®» surface, which prohibits bacterial colonisation. It has been shown that bone may even grow upwards along this surface in an oral direction.

#### 2. Material and Method

A 49-year old female patient, heavy-smoker, with a large list of pathologies (treated thyroid hyperfunction, multiple spinal herniae, lymphocytic colitis, monoclonal gammopathy u.a.) requested implant restoration due to severe aesthetic deficits and periodontal involvement in both jaws. (Fig. 1). The front teeth were in addition mobile.



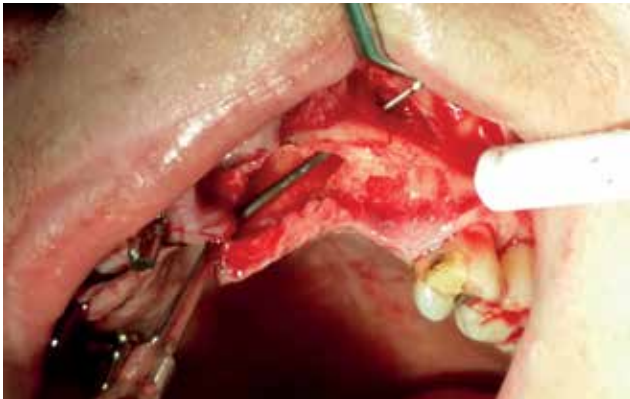**Fig. 1:** Pro-operative panoramic overview picture showing generalized bone loss and profound periodontal involvement around many teeth. The upper left canine is horizontally retained and impacted. Cranial to this tooth the residual bone height including the cortical of the nose is approximately 3 mm.

Technique: After a thorough intra-oral disinfection (using Betadine 5%) all teeth were removed in local anaesthesia. Tooth 23 was impacted on the palatal side of the maxillary crest, i.e. palatal to the roots of 21, 22. Hence a small flap had to be raised both towards the palatal and the vestibular side in order to access this area and to access the tip of the root of this tooth. The crestal cortical was removed over the crown. Then the crown of this canine was sectioned off its root and removed. After this the root is removed in one piece by chiselling it from the vestibular side into the direction of the void area left by the already removed crown of the canine.

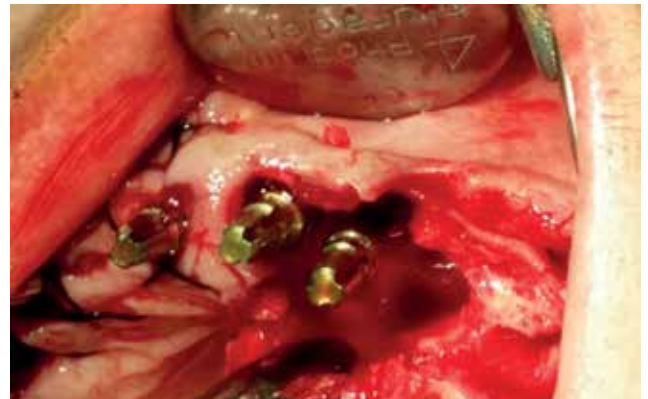
The upper jaw was immediately equipped with 10 BCS implants (Strategic Implant® Brand, Manufacturer Dr. Ihde Dental AG, CH-8737

Gommiswald, Switzerland) almost in the classic distribution<sup>1</sup> for an upper jaw (see Fig. 7):

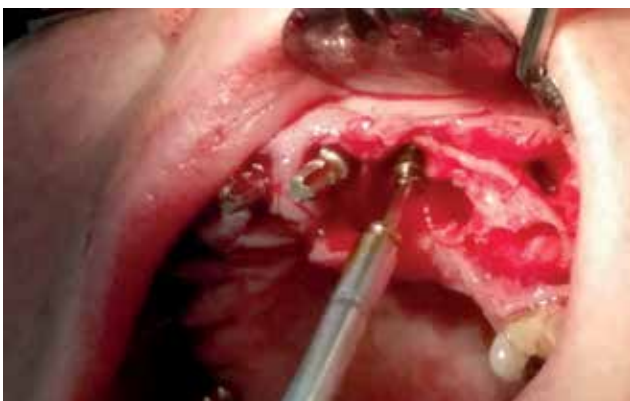- 2 implants were anchored in the tubero-ptyergoid region
- 4 implants were anchored in the floor of the nose as 2nd cortical
- another 4 implants were placed to minimize the distance between distal and anterior implants, all of them in cortical engagement in the floor of the maxillary sinus as 2nd cortical.



**Fig. 2:** Intra-operative view on the area of the retained tooth after its removal. The long probe shows the position of the removed canine and its direction, with the tip of the probe peaking out of the vestibular cortical in area 24. The tooth had been sectioned between crown and root and after removal of the crown the root was chiselled out easily from the vestibular side towards the centre of the osteotomy site.



**Fig. 4:** Clinical view of the two BCS-implants in the upper frontal area. The threads penetrate the cortical of the extracted canine (1st cortical) and the floor of the nose (2nd cortical). The bone height was less than 4 mm and for this reason a part of the thread of the left implant remained in the osteotomy socket. The extraction sockets of teeth 21 and 22 are not visible in this picture, they are located vestibular to the osteotomy site of the canine.

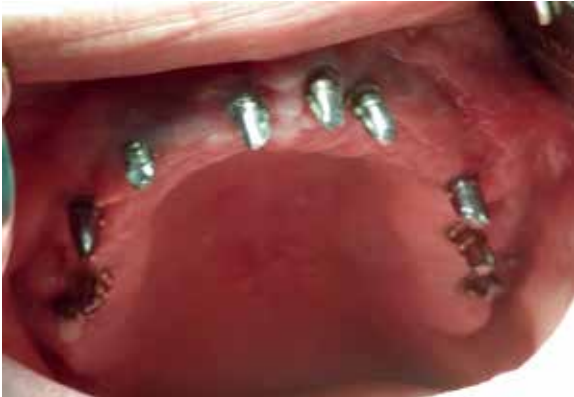

**Fig. 3:** After preparing a 2 mm diameter drill hole through the bony floor of the nose, 2 BCS implants are inserted into the osteotomy site of the upper left canine. The defect was then filled with «Hemospon» collagen sponge.

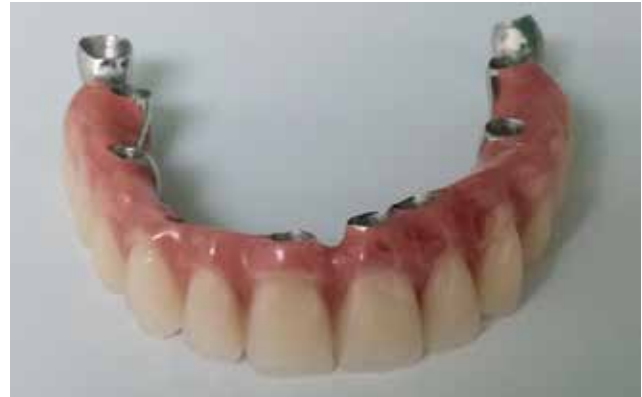All flaps were tightly closed with 3.0 silk suture and for local disinfection sufficient rinsing with Betadine® 5% solution was used. The whole treatment was performed without systemic antibiotics coverage, in accordance with the wishes of the patient.

### 3. Results

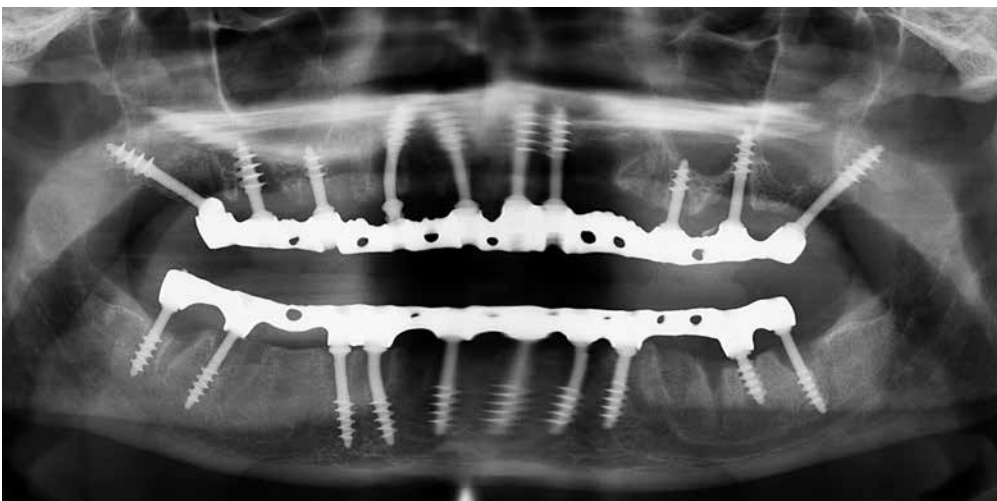
The healing was uneventful, although the patient utilized an (by herself) admitted amount of «10-15 cigarettes per day». The wounds in the upper jaw closed especially well, whereas in the lower jaw, which was treated 2 days later, some distances appeared.



**Fig. 5:** Clinical view of healed mucosa in the upper jaw on the 5th post-operative day; at this stage of the treatment the patient had already been using the long-term temporary bridge for 2 days. The bridge was just clicked in, without cement, and the patient was advised not to eat sticky food. Note the excellent healing of the soft tissues after daily cleaning with Betadine Solution (5%).



**Fig. 6:** Finished metal-to-plastic bridge before the cementation. The bridge contains teeth from 6-6 and distally two technical abutments



**Fig. 7:** Post-operative panoramic overview picture taken after insertion of the two bridges. Both jaws had been equipped with 10 implants. All implants except those in the lower front were placed in engagement to the 2nd cortical. The implants in area 21, 22 crossed vertically right through the extraction (osteotomy) site of the upper left canine and engaged in the cortical of the floor of the nose.

#### 4. Discussion

Because the initial treatment was finished in only a few days, the final level of the hard- and soft tissues could not be estimated then. If a lot of tissue shrinkage occurs, a 2nd bridge may become necessary in order to close the gaps between the bridge and the gums. Rebasings with pink acrylics directly inside the mouth is not a good option, because the new acrylic surface cannot be polished inside the mouth. Hence such a rebasing may give rise to chronic infections of the mucosa and this may even affect the peri-implant soft- and hard tissues badly.

We have observed however in innumerable cases, that patients even with large gaps between the bridge and the healed gums do not request a 2nd bridge, because they adapt their phonetics, they are well able to chew and function otherwise and long lips cover the aesthetically sensitive zone.

Although the treatment was done within eight days, both jaws were not operated on on the same day. The lower jaw was operated on on day three, the same day when the bridge in the upper jaw was delivered. We consider this protocol useful in cases where both jaws require treatment and when additional surgery (like the removal of impacted teeth) prolong the operation time significantly. The disadvantage of this procedure is however that the period of difficulties with the food uptake is longer and the patient's body is not provided with the necessary substrate. It may be owed to this detail of the treatment that the gums in the lower jaw showed a delay in healing.

We want to mention also that after the removal of retained upper wisdom teeth immediate placement of a Strategic Implant® is possible. In such cases finding the fusion area between the distal maxilla and the sphenoid bone (i.e. the pterygoid plate) is especially easy because this area is located directly behind the root of the wisdom tooth and the direction of the extraction socket allows easy drilling direction towards the ideal position of the implant's load transmitting thread.

#### 4. Conclusions

Since the amount of vertical bone is of no importance if the Strategic Implant® system is used, even after removal of impacted teeth (canines, 3rd molars, others). Immediate placement of implants is always possible, if the 2nd (or 3rd) corticals are available and being used.

The technology requires cortical engagement of the implant's thread in the 2nd cortical and immediate splinting through the bridge.

We have experienced for more than 10 years, that this treatment technology is simple and reliable, however it requires thorough and specific training.

#### References

- 1 Ihde S., Ihde A. Introduction into the work with a Strategic Implant®  
International Implant Foundation Publishing,  
Munich, 2015, ISBN 978-3-945889-01-5

